



Paws

ID :		Ref.by :	Dr.Paws
Name :	Dog Godzi	Requested :	9/2/2022
Age/Sex :	8 years	Reported :	14/2/2022

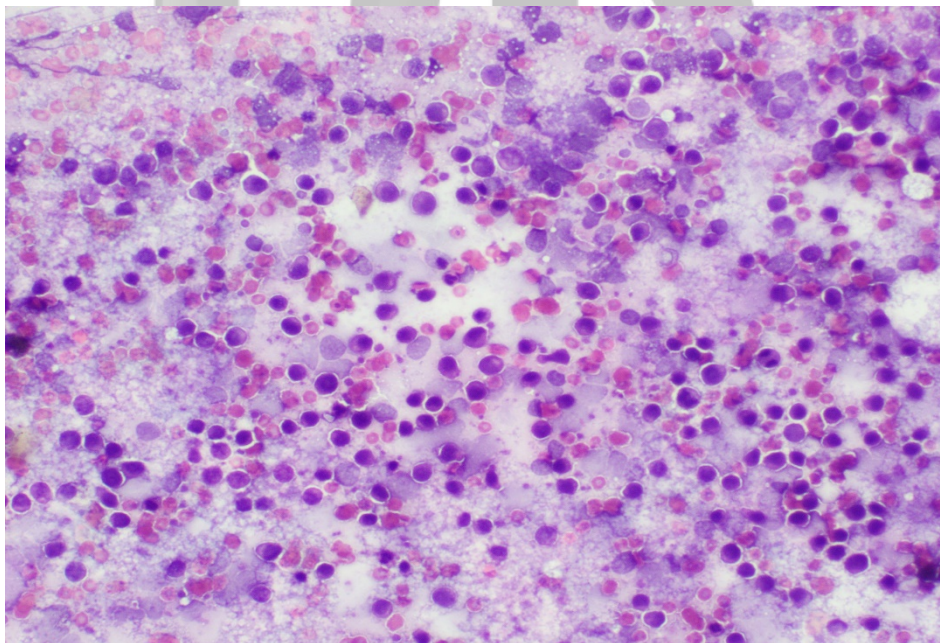
## Cytologicalreport

### Specimen Characteristics

Lymph node aspiration

### Microscopic Examination

Microscopy of submitted sample revealed abundant cellular yield of monomorphic immature medium to large lymphoid cells with dispersed chromatin and multiple prominent nucleoli. Large lymphoid cells were more than small lymphocytes. The lymphoid cells showed high nuclear cytoplasmic ratio, anisocytosis and anisokaryosis.



**Diagnosis:** lymphoma

**Pathologist:** Dr. Marwa Khattab, MD, PhD

Assistant professor of Pathology, Faculty of Veterinary Medicine, Cairo University



01008886446



Ahmed\_brkat@windowlive.com



www.dr-paws.com



التجمع الخامس - البنفسج 7 - صنية الرطب مقابل الزان - فيلا 212